

Viral particles in a papilloma from a green lizard (*Lacerta viridis*)

J. E. COOPER,¹ S. GSCHMEISSNER² & P. E. HOLT^{3*}

Departments of ¹Pathology and ²Anatomy, Royal College of Surgeons of England, 35-43 Lincoln's Inn Fields, London, WC2A 3PN, and ³Veterinary Surgery, Manchester Street, Oldham, Lancashire, OL8 1UF, United Kingdom

Papillomata are well recognized in lizards, particularly those of the genus *Lacerta* (Reichenbach-Klinke & Elkan, 1965). They appear to be transmissible by contact and are believed to be due to a virus. However, the only successful attempt to identify or isolate a viral agent was that by Raynaud & Adrian (1976), using electronmicroscopy, who described particles resembling herpesviruses, reoviruses and papovaviruses, in a green lizard (*Lacerta viridis*). In this paper we report the detection of viral particles in electronmicrographs of a papilloma from the same species.

Clinical history

The lizard was presented to one of the authors (PEH) on account of anorexia. No clinical abnormalities were detected and the lizard appeared to respond clinically to oral multivitamin therapy (SA-37; Intervet Laboratories Ltd, Cambridge, UK). 11 months later the lizard became anorexic again and on this occasion caseous stomatitis lesions—from which a *Proteus* sp. was cultured—were present, affecting the right mandible and hard palate. Grey, raised, spherical, dermal masses were noted behind the right ear, on the left thorax, left tail and over the left hip. The masses varied from 1 to 4 mm diameter and the largest (from the left hip region) was excised under general anaesthesia. Half of the mass was placed in a sterile container and the other half in formol-saline, and both were sent by post to another of the authors (JEC). The stomatitis lesions were debrided and dressed with a povidone-iodine preparation ('Povidine'; Berk Pharmaceuticals Ltd, Guildford, UK). Recovery from surgery was uneventful. A week later the lizard was eating with some difficulty, but by 2 weeks after the operation the stomatitis had extended to both sides of the mouth, the lizard was anorexic, and a firm, 10 mm diameter mass was palpable beneath the skin of the antero-lateral left abdomen. Despite supportive therapy the lizard died 4 weeks after surgery. The cause of death was attributed to necropsy to peritonitis associated with a

caseous abscess in the abdomen. Samples of various body organs in formol-saline and the eviscerated fresh carcass were submitted by express delivery to JEC.

Pathological examination

Histopathological examination of sections stained with Cole's haematoxylin and eosin confirmed the presence of an abscess in the body wall. The skin lesions were typical of papillomata, with marked proliferation of the epithelium and hyperkeratinisation.

A small amount of fresh papilloma was taken and fixed in 4% buffered glutaraldehyde for transmission electronmicroscopy. Routine processing was carried out and the tissue embedded in epoxy resin. Sections were cut, post stained with uranyl acetate and lead citrate, and examined with an electron microscope.

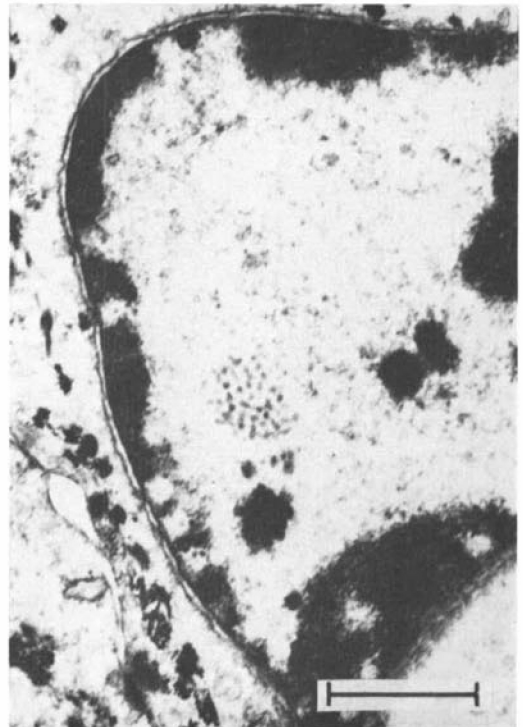


Fig. 1. Photomicrograph of an epithelial cell showing a cluster of viral particles within the nucleus. Line represents 600 nm.

*Present address: Department of Surgery, School of Veterinary Science, University of Bristol, Langford House, Langford, Bristol, BS18 7DU, UK.

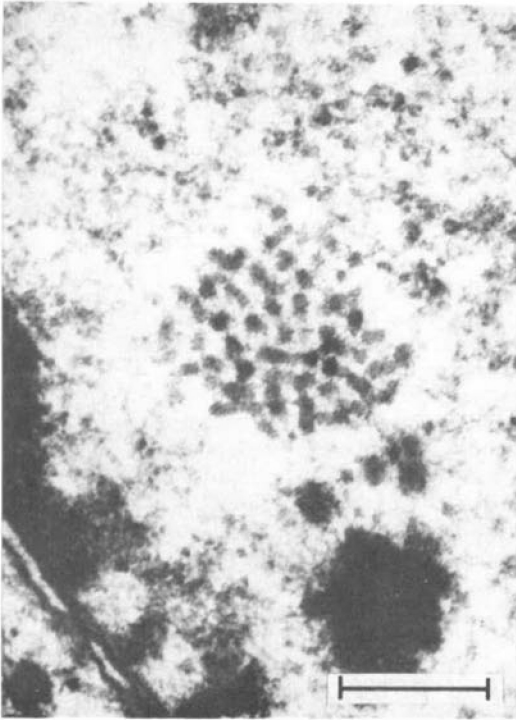


Fig. 2. Part of the cell shown in Fig. 1. Line represents 250 nm.

Cellular preservation, as denoted by general morphology, was good. The majority of epithelial cells examined showed no abnormality but the nuclei of a few contained small round inclusions (Figs 1 and 2). These resembled morphologically the virion of a typical papovavirus (Bonney, Koch, Confer & Dice, 1980), although smaller (25 nm diameter) than generally reported in the literature (Andrewes & Pereira, 1967).

Discussion

In the many examinations of reptilian papillomata undertaken by the present authors, this is the 1st where viral particles were detected, and appears to be only the 2nd time that they have been reported (Raynaud & Adrian, 1976). There is no proof that the virus seen was the causal agent but the findings suggest that more attention should be paid to electronmicroscopical examination of neoplasms from these species. Reptiles are not uncommonly kept in the laboratory (Cooper, 1977) and scientists working with such animals are in an excellent position to carry out detailed investigation.

References

- Andrewes, C. & Pereira, H. G. (1967). *Viruses of vertebrates*, 2nd ed. London: Baillière, Tindall & Cassell.
- Bonney, C. H., Koch, S. A., Confer, A. W. & Dice, P. F. (1980). A case report: a conjunctivocorneal papilloma with evidence of a viral etiology. *Journal of Small Animal Practice* **21**, 183-188.
- Cooper, J. E. (1977). Diseases of lower vertebrates and biomedical research. *Laboratory Animals* **11**, 119-123.
- Raynaud, A. & Adrian, M. (1976). Lésions cutanées à structure papillomateuse associées à des virus chez le lézard vert (*Lacerta viridis* Laur). *Compte rendu hebdomadaire des séances de l'Académie des sciences, Paris* **283D**, 845-847.
- Reichenbach-Klinke, H. & Elkan, E. (1965). *The principal diseases of lower vertebrates*. London: Academic Press.
-

Viruspartikel in einem Papillom einer Smaragdeidechse (*Lacerta viridis*)

J. E. COOPER, S. GSCHMEISSNER & P. E. HOLT